

THE REPORT OF PERIAPICAL ABSCESS IN CARNASSIAL TOOTH IN AN EURASIAN LYNX (*LYNX LYNX*)

Rostami, A¹, Dehghan, M. M.¹, Masoudifard, M.¹, Memarian, I.², Shahi Ferdous, M. M.³

¹Department of Clinical Science, Faculty of Veterinary Medicine, University of Tehran

²Undergraduated DVM student, Faculty of Veterinary Medicine, University of Tehran, P.O.Box.: 14155-6453, Email: animal_protector19@yahoo.com

³D.V.M., Faculty of Veterinary Medicine, University of Tehran.

Summary:

The Eurasian Lynx (*Lynx lynx*), was once considered a subspecies of the bob-tailed cat complex. The Eurasian Lynx has been reported in different areas from North-west to North-east provinces of Iran. The scientific literature cites numerous types of pathological dental conditions that occur spontaneously in free-ranging populations. Abscessed teeth occur frequently. An adult female Eurasian Lynx was referred to Small Animal Hospital, Faculty of Veterinary Medicine, University of Tehran. In physical examination a wound with purulent exudates on the face was observed. Also in the left upper carnassial tooth and molar, dental caries and sever gingivitis were determined. The radiographic evaluation was indicated of periodontal (periapical) abscess of the left upper carnassial tooth. By using an elevator, the roots of carious carnassial tooth and molar were loosened from the periodontal ligament and the teeth were extracted by tooth extraction forceps. The abscess, fistula and the wound were derided and irrigated with copious amount of normal saline solution. After surgery, antibiotic therapy was continued by intramuscular administrating of 30mg/Kg BW, Ceftriaxon.

Introduction:

The Eurasian Lynx (*Lynx lynx*) (Fig. 1), was once considered a subspecies of the bob-tailed cat complex that includes the Canada Lynx (*Lynx Canadensis*), Iberian Lynx (*Lynx pardinus*), and the Bobcat (*Lynx rufus*). Today, most scientists consider these four cats to be separate species, with the Eurasian Lynx being the largest in size, as well as distribution (FIROUZ 2000). The Eurasian Lynx has been reported in different areas from North-west to North-east provinces of Iran (Fig. 2) (ZIAIE 1996).



Fig 1: *Lynx lynx*

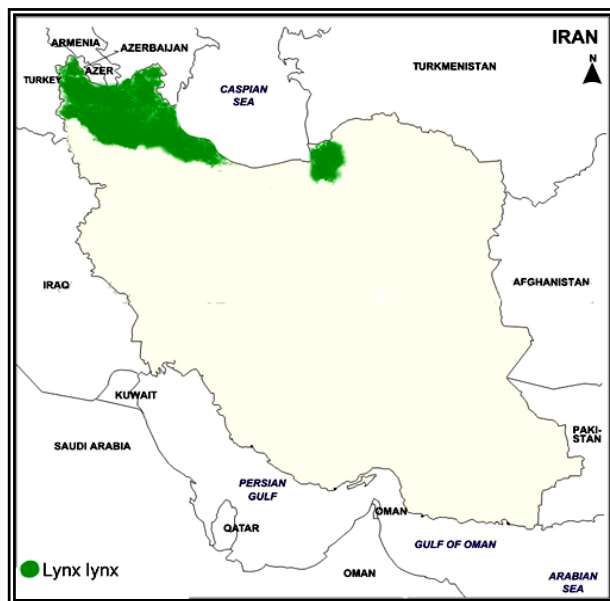

Fig. 2: Distribution of *Lynx lynx* in Iran (ZIAIE 1996)

The increasing urbanization and domestication of Western Europe, and the resulting significant loss of habitat and diminished prey base, have led to a severe reduction of the Eurasian Lynx population. The scientific literature cites numerous types of pathological dental conditions that occur spontaneously in free-ranging populations. Dental problems often may not manifest themselves in conspicuous ways. Chronic weight loss and malnutrition may have various dental origins, ranging from acute sepsis and pain to malocclusion or oligodontia (FOWLER 1986). Abscessed teeth occur frequently. The abscess may be secondary to periodontitis or fractures of the crown of teeth. The clinical signs of abscessed teeth may range from a unilateral swelling of the mandible or maxilla on the affected side to draining facial fistulas (WALLACH AND BOEVER, 1983).

Even with the limits on our current knowledge, there are numerous opportunities for both preventive and therapeutic solutions to dental disease in zoo animals.

Case history:

An adult female Eurasian Lynx was referred to Small Animal Hospital, Faculty of Veterinary Medicine, University of Tehran. On the case history she had an old wound on the left side of her face (Fig. 3). In physical examination a wound with purulent exudates on the face was observed. Also in the left upper carnassial tooth and molar, dental caries and sever gingivitis were determined. Blood sample was taken to carry out complete blood cell count (CBC). Through sampling for bacterial culture of the wound it was observed that the wound has related to the oral cavity by a fistula which was opened to the gingiva next to the carious molar (Fig. 4). Open mouth and lateral ra-

diograph were done up and then she was referred to surgery section.



Fig. 3: The wound with purulent exudates on the face.

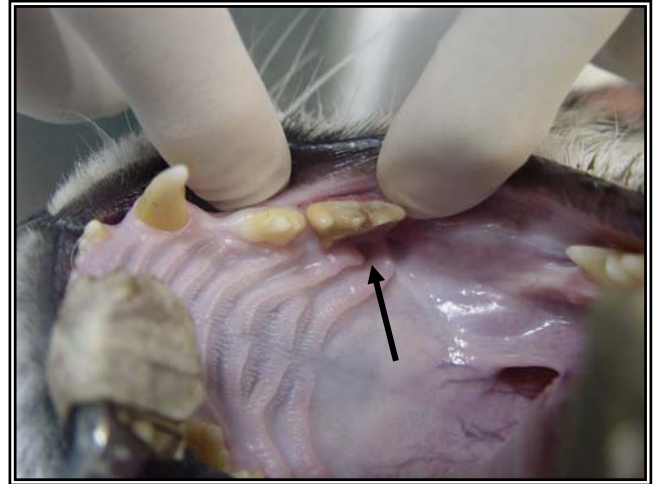


Fig. 4: The carious carnassial tooth and the opening of the fistula (Arrow).

RESULTS AND DISCUSSION:

The result of the complete blood cell count was mentioned in Table 1.

Table 1: CBC results

HCT	35%
WBC	16250/ μ L
Neutrophils	54%
Bands	0%
Lymphocytes	24%
Monocytes	3%
Eosinophils	19%
Basophils	0%

Radiography revealed a zone of radiolucency surrounded the apex of caudal root of the left upper carnassial tooth. The apex of the tooth root and the alveolar bone were partially resorbed. Meanwhile the pulp cavity of the carnassial tooth seemed to be enlarged. The radiographic changes were indicative of periodontal (periapical) abscess of the left upper carnassial tooth (Fig. 5).

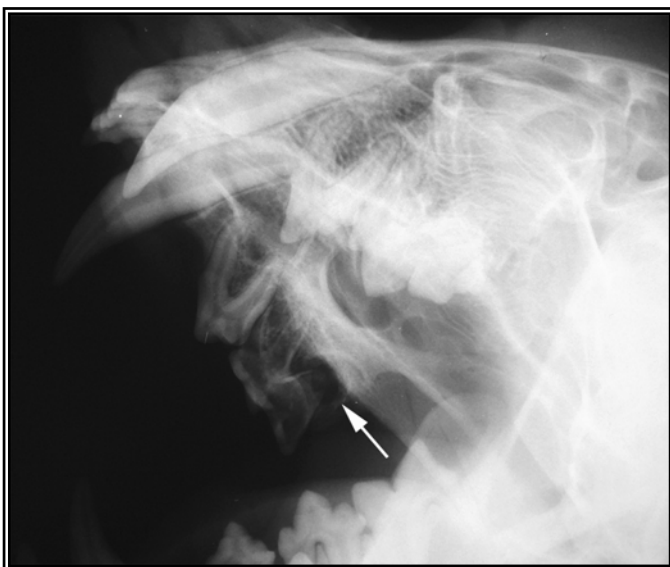

Fig. 5: Open mouth right ventral- left dorsal oblique view of maxilla - the radiolucency around the apex of caudal root of the upper carnassial tooth (arrow) and decreased alveolar bone density of lamina dura consistent with periodontal (periapical) abscess.

Arcanobacter pyogenes was detected in bacterial culture. Based on the results of antibiogram, antibiotic therapy was done by intramuscular administering 20_{mg}/Kg BW, Amikacine (IPDIC, Rasht-Iran), bid for 5 days, before surgery. Anesthesia was induced by intramuscular injection a combination of 10_{mg}/Kg BW, Ketamin 10% (alfasan, WOERDEN-HOLLAND) and 5_{mg}/Kg BW, Xylazine 2% (alfasan, WOERDEN-HOLLAND) and was continued by intravenous injection of 5_{mg}/Kg BW, Ketamin (alfasan, WOERDEN-HOLLAND) and 1_{mg}/Kg BW, Diazepam (ZEPADIC 10mg/2ml, IPDIC, Rasht-Iran). By using an elevator, the roots of carious carnassial tooth and molar were loosened from the periodontal ligament and the teeth were extracted by tooth extraction forceps. The abscess, fistula and the wound were debrided and irrigated with copious amount of normal saline solution (Fig. 6).

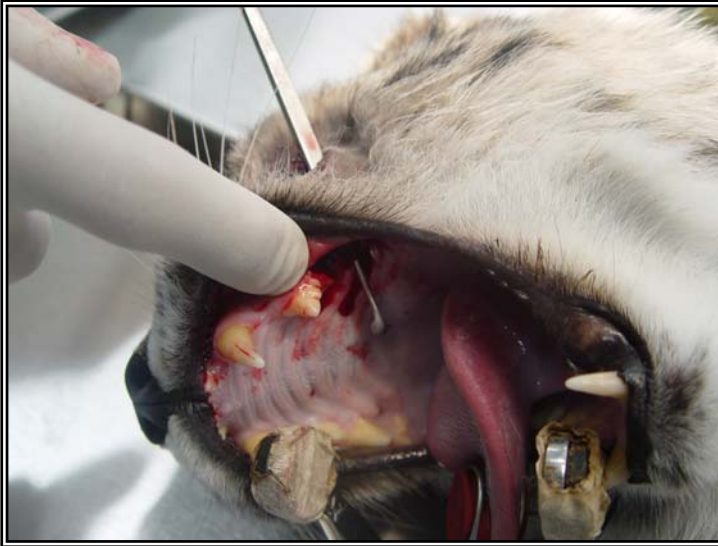

Fig. 6: The abscess, fistula and the wound were debrided

Table 2: CBC one month post treatment.

HCT	40%
WBC	10500/ μ L
Neutrophils	58%
Bands	0%
Lymphocytes	32%
Monocytes	0%
Eosinophils	10%
Basophils	0%

After surgery, antibiotic therapy was continued by intramuscular administrating of 30_{mg/Kg BW}, Ceftriaxon-500mg, (EXIR, Borugerd-Iran), bid for 5 days. Liquid meal was prescribed till 48 hours and raw meat was consumed for next two weeks. Treatment was successful after one month. The result of the complete blood cell count, after treatment, was mentioned in Table 2.

A periodontal abscess occurs in the periodontal tissues. Such abscesses are often deep-seated, affecting the area surrounding the tooth root. When they occurred around the apex of the tooth, they are referred to as periapical abscesses. An abscess may be the result of periodontal disease, trauma, cyst formation, neoplasia or a retained root following tooth extraction (KEALY AND MC ALLISTER, 2000).

The systemic consequences of dental disease are likely to be greater in the geriatric patient, in which concurrent diseases in multiple organ systems are more likely and dental attrition due to age becomes an added factor. Surgical manipulations usually require general anesthesia, and this added risk must be considered. The best strategy should be directed toward having patients enter their later stages of life with as few cumulative dental problems as is practical.

In aged carnivores, molar wear may eventually cause pulp exposure and formation of a dentoalveolar abscess. Because of the infrequency with which large carnivores may be handled, particularly for elective dental radiography, the mechanisms for dental self-repair and the frequency of its failure are not well understood.

REFERENCES:

- FIROUZ E (2000): Wildlife of Iran, 1st ed., Tehran, Iran University Press, 358.
- WALLACH J D AND BOEVER W J (1983): Diseases of exotic animals, Medical and surgical management. Philadelphia, W.B. Saunders Company, 380-382.
- FOWLER ME (1986): Zoo and Wild Animal Medicine. Pennsylvania, USA: WB Saunders Company, 533-547.
- KEALY JK AND MC ALLISTER H (2000): Diagnostic Radiology and Ultrasonography of the Dog and Cat, 3rd ed., Philadelphia, W.B. Saunders Company, 364-365.
- ZIAIE H (1996): Field guide to the mammals of Iran, Tehran, Department of Environment Inc., company, 234-235.